

## Head and Neck, Eyes, Ears, Nose, & Throat

## Head & Neck

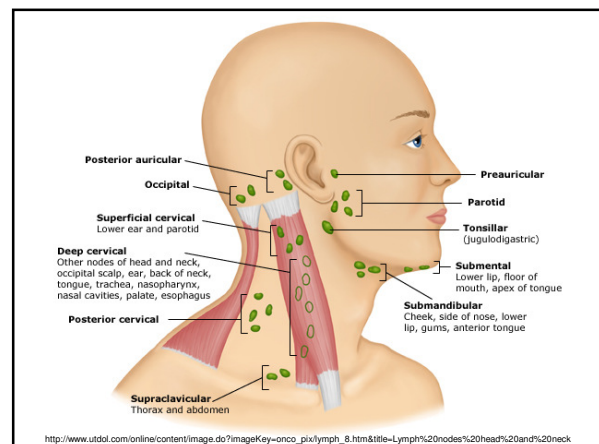
- Review Anatomy of head
- History
  - Headache
  - Head Injury
  - Dizziness
  - Neck pain
  - Lumps, swelling
  - Surgery

## Head & Neck Exam

- Inspect and Palpate skull
- Inspect face
- Inspect and palpate neck
  - ROM
  - Lymph nodes – know the names
  - Trachea
  - Thyroid gland

## Head & Neck Exam

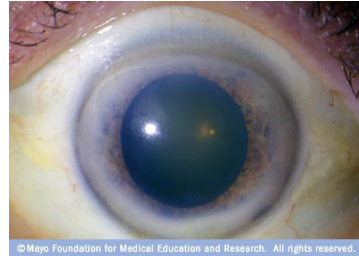
- Abnormal findings,
  - Goiter
  - Grave's disease
  - Adenopathy
  - Neck masses



## Eyes

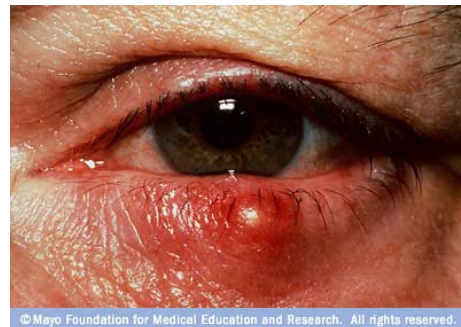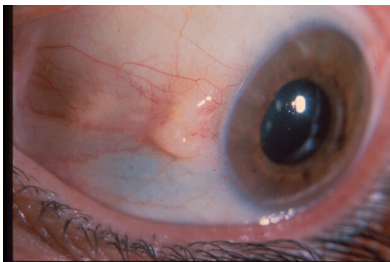
- Review A&P – 208 -214
- Review Aging Adult changes

## Arcus Senilis

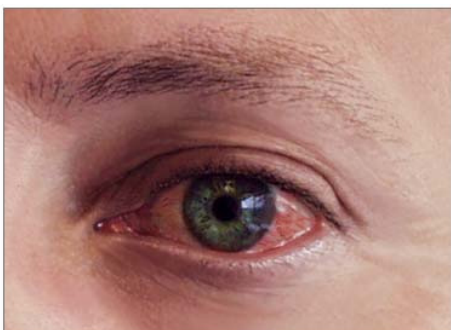


© Mayo Foundation for Medical Education and Research. All rights reserved.

## Pterygium

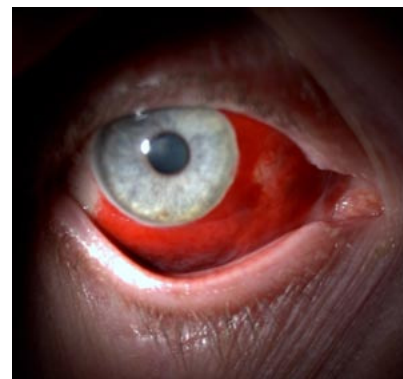


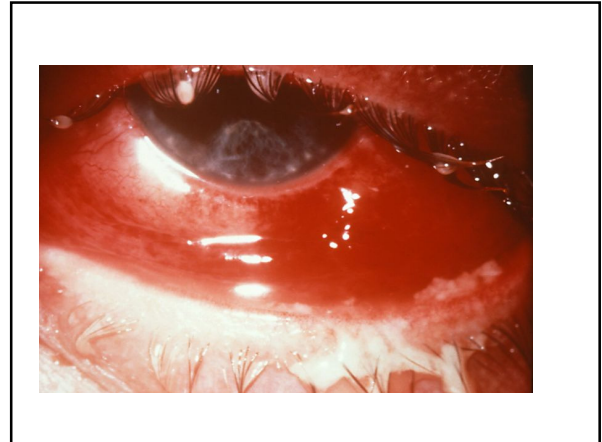© Mayo Foundation for Medical Education and Research. All rights reserved.



Conjunctivitis

ADAM.





### Eye: History

- Visual problems or changes
  - Sudden loss of vision is ALWAYS an emergency
- Pain
- Strabismus, diplopia
- Redness, swelling
- Past history of ocular problems
- Glaucoma

### Eye: History

- Glasses or contacts
- Self care behaviors
- Medications
- Vision loss

### Eye: Physical Exam

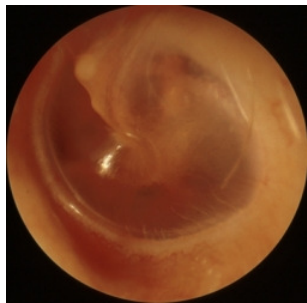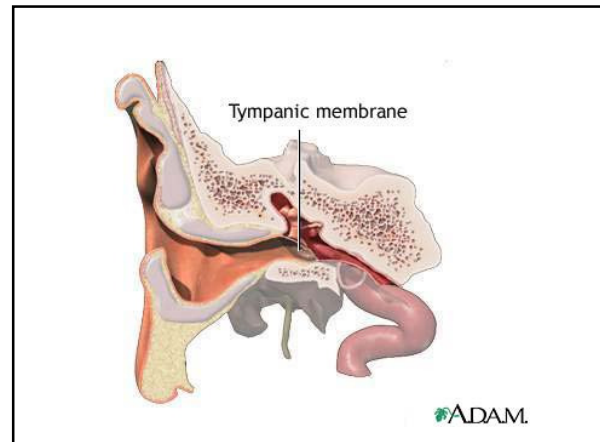
- Visual acuity
- Test visual fields
- Extraocular muscle (EOM)
  - Corneal Light reflex
  - Diagnostic Positions of gaze
- Inspection of External structures
  - General
  - Eyebrows
  - Eyelids and lashes (lag, ptosis, closure)

### Eye: Physical Exam

- Eyeball
- Conjunctiva and Sclera
- Lacrimal status
- Cornea and lens
- Iris & Pupil
  - PERRLA
- Ocular Fundus
- Findings: arcus senilis, conjunctival hemorrhage, ophthalmic herpes, ptosis

## Ear

- Review A&P, pg 289 - 295
- History
  - Earache
  - Infections
  - Discharge
  - Hearing Loss
  - Environmental noise
  - Tinnitus
  - Vertigo
  - Self-care

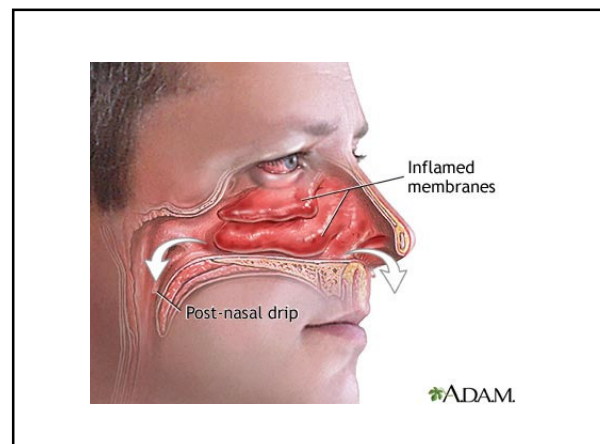


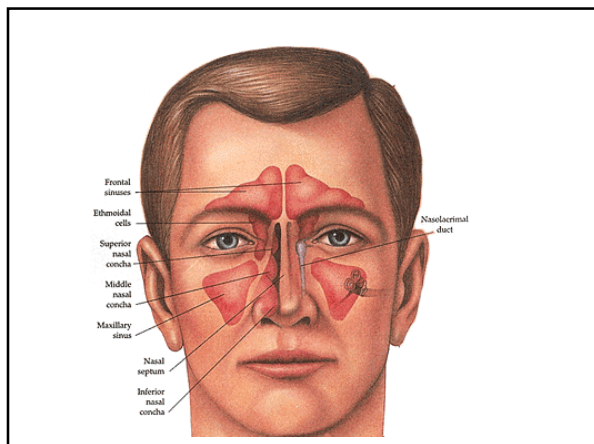
## Ear: Physical Exam

- Size and shape of Pinna
- Tenderness
- External meatus
- Otoscope pg 308 for normal with landmarks; 317 for serous otitis
  - EAC
  - TM
- Hearing tests
  - Whispered voice, Weber, Rinne
- Romberg

## Nose, Mouth, Throat

- Review A&P, 321 - 327
- History: Nose
  - Discharge
  - Infections/Colds
  - Sinus Pain
  - Trauma
  - Epistaxis
  - Allergies





## Nose, Mouth, Throat

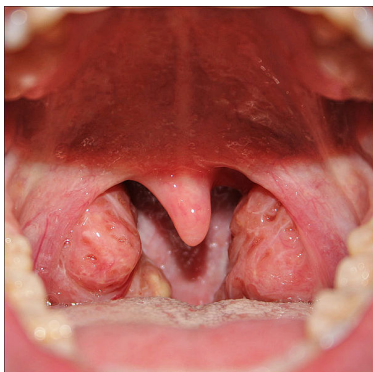- **History: Mouth & Throat**
  - Sores & Lesions
  - Sore Throat
  - Bleeding gums
  - Toothache
  - Hoarseness
  - Dysphagia
  - Altered Taste
  - Smoking, ETOH
  - Self-care

## Nose: Physical Exam

- Inspect
  - Outer Nose
  - Nasal Cavity
  - Sinuses
- Palpate or Percuss Sinuses
  - Sinuses

## Mouth & Throat: Physical Exam

- Inspect Mouth & Throat
  - Lips
  - Dentition
  - Gums
  - Buccal Mucosa
  - Tongue
  - Palate
  - Pharynx
    - Uvula, pillars, tonsils, laryngeal wall
  - Palpate tongue, sublingual



## Mouth & Throat Abnormal

- Herpes simplex, pg 333
- Gingival hypertrophy in a phenytoin patient, 337
- Oral Candidiasis (Thrush), pg 340
- Enlarged tonsils, pg 347

